

Visual Performance of a Small-Aperture Intraocular Lens: First Comparison of Results After Contralateral and Bilateral Implantation

Robert Edward Ang, MD

ABSTRACT

PURPOSE: To evaluate visual performance in patients implanted contralaterally and bilaterally with the small-aperture hydrophobic acrylic intraocular lens (IOL) (IC-8 IOL; AcuFocus, Irvine, CA).

METHODS: In this prospective, non-randomized, non-comparative study, 10 contralateral patients were implanted with a monofocal IOL in one eye and an IC-8 IOL in the other. There were 10 bilateral patients implanted with an IC-8 IOL in both eyes. All patients were observed for at least 12 months after the study device was implanted in each eye. Visual acuity, patient satisfaction, ease of task performance, visual symptoms, defocus curves, and contrast sensitivity comparisons are presented.

RESULTS: For bilateral and contralateral patients, the mean uncorrected and corrected distance binocular acuities were 20/25 or better at all distances. All 10 (100%) contralateral

and 10 (100%) bilateral patients achieved 20/32 or better binocular uncorrected and corrected distance visual acuity at all distances. The improvement in binocular uncorrected intermediate and uncorrected near visual acuity was 0.5 to 1 line greater in bilateral patients. Bilateral implantation extended the depth focus range by 0.25 diopters. The mean log contrast sensitivity was similar in both groups for mesopic without glare and with glare conditions at all spatial frequencies ($P > .05$). Bilateral patients had better overall satisfaction, satisfaction with near tasks, and spectacle independence and they rated many near tasks as easier to perform.

CONCLUSIONS: Results demonstrate that both contralateral and bilateral implantation of an IC-8 IOL provide excellent visual acuity across all distances. Bilateral implantation can be successful based on careful patient selection and optimization of refractive targets.

[*J Refract Surg.* 2020;36(1):12-19.]

The small-aperture intraocular lens (IOL) (IC-8 IOL; AcuFocus, Irvine, CA) is a one-piece, hydrophobic acrylic, posterior chamber monofocal IOL that provides increased range of vision from far to near, by extending the depth of focus.^{1,2} It works by eliminating the unfocused peripheral light rays while the central rays pass unaffected and focus on the retina.³ Reducing the size of the blur circle from unfocused peripheral light improves the image resolution for intermediate and near vision, with minimal to no change to distance vision.

The IC-8 IOL is indicated for contralateral implantation in conjunction with an aspheric monofocal IOL im-

plantation in the fellow eye. Grabner et al.¹ published a 12-month pilot evaluation on 12 patients implanted with the IC-8 IOL. In this study, the fellow eye was either treated with a monofocal IOL or remained phakic depending on cataract status. After this first publication, the study was amended to allow bilateral implantation of the IC-8 IOL for those patients whose fellow eye was not yet pseudophakic. Patients were implanted with a second IC-8 IOL if they were satisfied with their first eye results and asked for implantation of the IC-8 IOL in the fellow eye. In accordance with the requirements of the ethics committee, a total of 20 patients completed

From Asian Eye Institute, Makati City, Philippines.

© 2020 Ang; licensee SLACK Incorporated. This is an Open Access article distributed under the terms of the Creative Commons Attribution 4.0 International (<https://creativecommons.org/licenses/by/4.0>). This license allows users to copy and distribute, to remix, transform, and build upon the article, for any purpose, even commercially, provided the author is attributed and is not represented as endorsing the use made of the work.

Submitted: August 28, 2019; Accepted: November 14, 2019

Dr. Ang has received grants from AcuFocus and PhysIOL.

Correspondence: Robert Edward Ang, MD, 8th Floor Phinma Plaza Rockwell Center, Makati City 1200, Philippines. E-mail: angbobby@hotmail.com
doi:10.3928/1081597X-20191114-01

the study; 10 patients were implanted contralaterally and 10 bilaterally with the IC-8 IOL.

The main purpose of this clinical investigation was to evaluate the visual effects of bilateral implantation of the IC-8 IOL in comparison to contralateral implantation. Visual acuity, patient satisfaction, ease of task performance, visual symptoms, defocus curves, and contrast sensitivity comparisons are presented.

PATIENTS AND METHODS

STUDY DESIGN

This was a prospective, non-randomized, non-comparative, open-label study (European Databank for Medical Devices, CIV-AT-13-07-011473). The study was performed in accordance with the tenets of the Declaration of Helsinki and approved by the Asian Eye Institute Ethics Review Committee for the investigational site. Patients were screened for eligibility, and informed consents were obtained from all eligible patients.

All patients underwent cataract extraction by phacoemulsification followed by implantation of the study device(s). Of the 10 contralateral patients, 8 patients received a monofocal IOL before enrolling in the study and 2 patients were first implanted with the IC-8 IOL in the worse eye followed by the monofocal IOL in the second eye within 3 months. In 6 of the 10 bilateral patients, the IC-8 IOLs were implanted at least 5 months apart. In 4 patients, the interval between implantations was approximately 1 month or less. All patients were observed for at least 12 months after the study device was implanted in each eye.

ELIGIBILITY CRITERIA

Included were patients with visually significant cataract, age of 18 years or older, corrected distance visual acuity (CDVA) of 20/30 or worse, potential visual acuity of 20/25 or better, and topographical corneal astigmatism up to 1.75 diopters (D). Patients were included for bilateral implantation after successful IOL implantation in the first eye, postoperative CDVA of 20/25 or better in the first eye, postoperative manifest refractive cylinder of 0.75 D or less in the first eye, preoperative topographical corneal astigmatism of less than 1.00 D in the second eye, no unresolved adverse events or severe visual symptoms in the first eye, and minimum mesopic pupil size of 5 mm in both eyes. Additionally, patients had to voluntarily express their desire to have the IC-8 IOL in the second eye.

DEVICE DESCRIPTION AND SURGICAL TECHNIQUE

The IC-8 IOL is a sterile, single-use, one-piece hydrophobic acrylic IOL with a centrally located, embedded polyvinylidene difluoride annular mask intended to improve near vision based on the concept of small-aperture

optics. The embedded annular mask has an outer diameter of 3.23 mm with a central aperture measuring 1.36 mm in diameter and contains 3,200 microperforations on its annulus (sparing the periphery) ranging in size from 7 to 10 μm in diameter and arranged in a pseudorandom fashion. A detailed description of the device and surgical technique has been previously published.^{1,2}

The IC-8 IOL eye in the contralateral and bilateral patients was targeted for 0.50 to 0.75 D of myopic postoperative manifest refractive spherical equivalent (MRSE). The monofocal IOL eye in contralateral patients was targeted for emmetropia. For bilateral patients, the IOL power selection for the first eye was targeted for myopia (-0.50 to -0.75 D) and the second eye for emmetropia. If desired near or intermediate outcomes were not achieved in the first eye, then the second eye was targeted for more myopia.

IOL BIOMETRY

The IOLMaster 500 (Carl Zeiss Meditec, Jena, Germany) and the Barrett Universal II formula using an A-constant of 120.5 were used to calculate IOL power.

VISUAL ACUITY TESTING

Visual acuities were measured using the Early Treatment Diabetic Retinopathy Study (ETDRS) chart in the Optec 6500 Vision Tester (Stereo Optical Co., Chicago, IL) at 1, 3, 6, 9, and 12 months postoperatively. Visual acuities were recorded as number of correctly read letters. Binocular uncorrected (UDVA) at 6 m, intermediate (UIVA) at 80 cm, near (UNVA) at 40 cm, CDVA, distance-corrected intermediate (DCIVA), and distance-corrected near (DCNVA) visual acuities were measured.

BINOCULAR DEFOCUS CURVE

Binocular defocus curve testing was performed while viewing an ETDRS lightbox at 4 m under standard photopic conditions, using midpoint refraction. The technician first defocused the image by placing a +5.00-D lens in front of the eye, and then progressively changed the defocus lens in 0.50-D increments from +5.00 to -5.00 D. Visual acuity measurements were obtained through each defocus step. Defocus curve testing was administered at 3 and 6 months postoperatively.

CONTRAST SENSITIVITY TESTING

Binocular photopic and mesopic contrast sensitivity with and without glare testing of the second eye was performed on all patients at 6 months postoperatively with the Functional Acuity Contrast Test (FACT) chart in the Optec 6500. Contrast sensitivity was tested at frequencies of 3, 6, 12, and 18 cycles/degree (cpd) for photopic condition and 1.5, 3, 6, and 12 cpd for me-

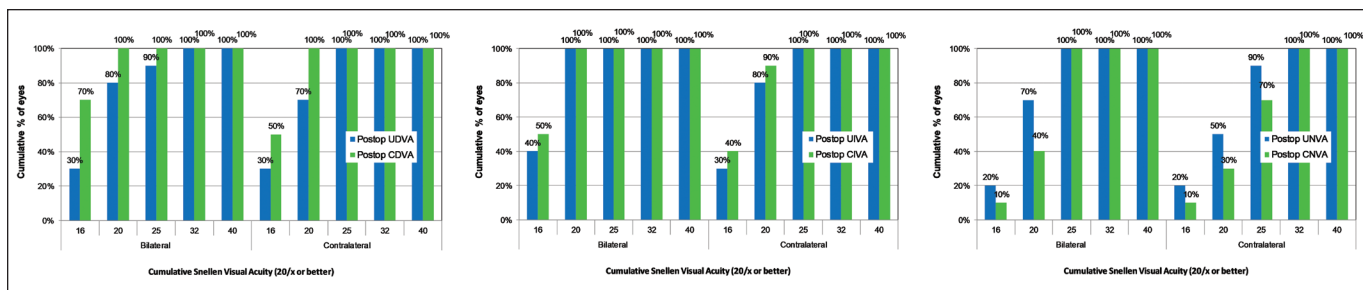


Figure 1. Histogram of postoperative binocular uncorrected and corrected distance visual acuity at far (left, UDVA and CDVA), intermediate (center, UIVA and DCIVA), and near (right, UNVA and DCNVA) for the bilateral and contralateral groups.

sopic condition. The impact of the floor effect of not seeing any contrast sensitivity patches was taken into consideration by assigning a value of 0.3 log contrast sensitivity below the first patch (highest contrast patch) to patients who were not able to identify any patches.^{4,5}

PATIENT-REPORTED OUTCOMES

Patient-reported outcomes including satisfaction and visual symptoms were assessed through a subjective questionnaire with a 7-point scale preoperatively and 3, 6, and 12, months postoperatively. Patient satisfaction and task performance were assessed binocularly. Patients rated their satisfaction with overall vision, near vision without reading glasses, frequency of using reading glasses, and ease of performing near or distance tasks on a scale of 1 to 7, with 1 being “very dissatisfied” or “all the time” (for frequency of using reading glasses) or “not at all easy” (for ease of performing tasks) and 7 being “very satisfied” or “never” (for frequency of using reading glasses) or “very easy” (for ease of performing tasks).

Visual symptoms were assessed monocularly, including blurry/fluctuating vision, color disturbances, distortion, dryness, glare, halos, night vision problems, pain/burning, double vision, and ghost/overlapping images. Patients reported the presence (“Yes” or “No”) and severity (scale of 1 “very mild” to 7 “very severe”) of these symptoms. For data analysis, a “No” was treated as 0 in the severity rating.

STATISTICAL ANALYSIS

Statistical analysis was performed using JMP statistical software (version 13.0; SAS Institute, Inc., Cary, NC). ETDRS letter scores were converted to logMAR units for data reporting. For each IOL group, mean, standard deviation (SD), and 95% confidence intervals (CIs) of logMAR values were calculated. Due to the small sample size without normal distribution, mean comparisons for continuous parameters were performed with the non-parametric Wilcoxon test. Patient-reported outcomes including satisfaction scores and visual symptom ratings were treated as continuous variables for mean comparisons. A *P* value of

less than .05 was considered to be statistically significant. For visual symptom reporting, an average of the two eyes was taken within each patient from monocular symptom data at the respective time point before calculating the group means.

RESULTS

DEMOGRAPHICS AND MRSE

The mean ± SD age of the 20 patients was 62.6 ± 6.2 years (range: 52 to 73 years). Of the 20 patients, 13 (65%) were female and 7 (35%) were male. The mean ± SD (95% CI) MRSE for the IC-8 IOL eyes in bilateral and contralateral patients for the preoperative and all postoperative visits, as well as the preoperative corneal astigmatism, are presented in **Table A** (available in the online version of this article).

BINOCULAR VISUAL ACUITIES

Figure 1 shows the distributions of binocular UDVA and CDVA at far, intermediate, and near at 12 months in contralateral and bilateral patients, respectively. All 10 (100%) contralateral and 10 (100%) bilateral patients achieved 20/32 or better binocular UDVA and CDVA at all distances.

Figure 2 shows the differences in Snellen lines for both groups between binocular UDVA and CDVA at far (left), intermediate (center), and near (right) at 12 months postoperatively. In both groups, the CDVA and DCIVA of almost all patients remained unchanged or improved by one Snellen line compared to the UDVA and UIVA, respectively. At near vision, the DCNVA of half of the patients in both groups remained unchanged compared to UNVA. In the contralateral group, the second half of patients had a loss of one Snellen line; in the bilateral group, 1 patient had a loss of two Snellen lines and 1 patient had a one Snellen line improvement in DCNVA compared to UNVA.

Figure 3 shows the mean logMAR binocular UDVA and CDVA at far (left), intermediate (center), and near (right) in contralateral and bilateral patients over a postoperative period of 12 months. Except for UIVA at 1 month (*P* = .049) and 6 months (*P* = .043), there was

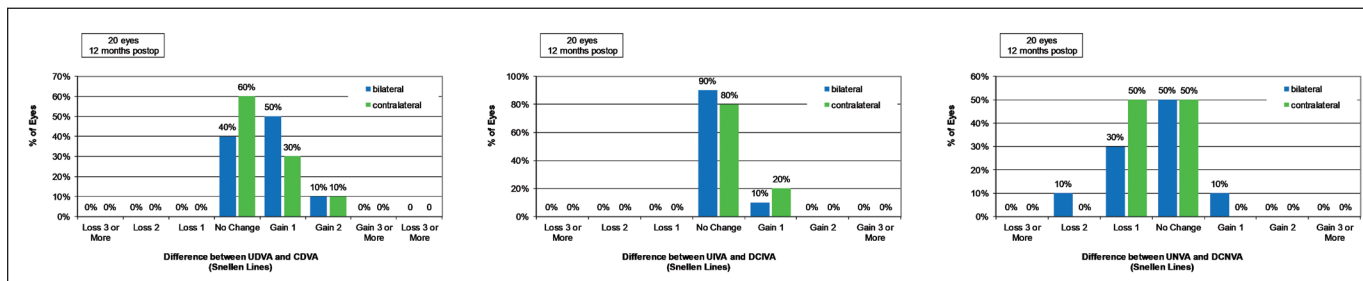


Figure 2. Histogram of difference in Snellen lines between binocular uncorrected and corrected distance visual acuity at far (left, UDVA and CDVA), intermediate (center, UIVA and DCIVA), and near (right, UNVA and DCNVA) for the bilateral and contralateral groups.

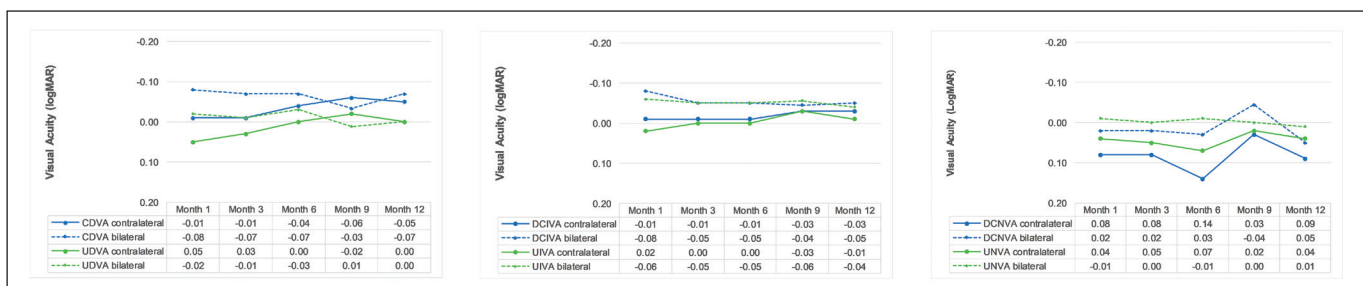


Figure 3. Mean logMAR binocular uncorrected and corrected distance visual acuities at far (left, UDVA and CDVA), intermediate (center, UIVA and DCIVA), and near (right, UNVA and DCNVA) in contralateral and bilateral patients in the postoperative period from 1 to 12 months following the implantation in the second eye.

no clinically relevant change (0.1 logMAR) to UDVA at all distances in both groups and the improvement to UDVA remained stable over 12 months ($P > .05$). There were no significant differences in mean uncorrected visual acuities between contralateral and bilateral patients at any postoperative time points ($P > .05$).

CDVA, DCIVA, and DCNVA were significantly different between the contralateral and bilateral patients at 1 month for DCIVA ($P = .018$), 3 months for CDVA ($P = .010$), and 6 months for DCNVA ($P = .018$). All distance-corrected visual acuities remained stable over 12 months postoperatively ($P > .05$).

BINOcular DEFOCUS CURVE

Figure 4 shows the mean binocular distance-corrected defocus curve (+5.00 to -5.00 D) for contralateral and bilateral patients at 12 months after the second eye implantation. At 0.2 logMAR (20/32 Snellen equivalent) or better visual acuity, the defocus range was +1.50 to -2.00 D for contralateral patients and +1.25 to -2.25 D for bilateral patients. The defocus curve for bilateral patients shifted approximately 0.25 D to the negative defocus direction, which effectively expanded the near vision range by 0.25 D and improved the visual acuities by 0.5 line at the intermediate and near distances.

CONTRAST SENSITIVITY

Figure 5 shows mean binocular contrast sensitivity for contralateral and bilateral patients at 12 months. The

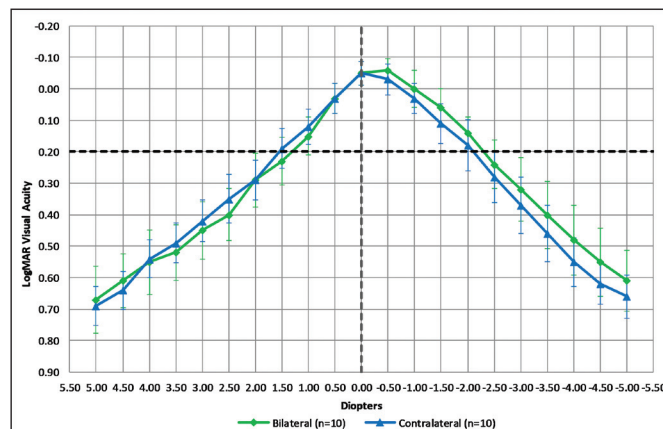
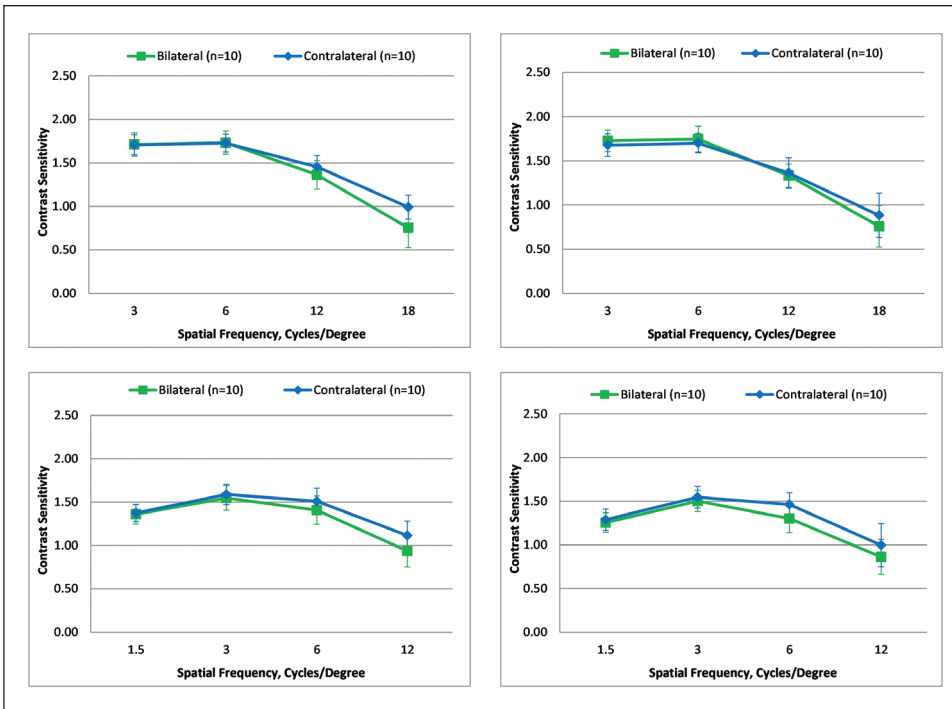


Figure 4. Mean binocular distance-corrected defocus curves on contralateral and bilateral patients at 12 months. Defocus ranges from +5.00 to -5.00 diopters. Error bars represent 95% confidence intervals.

mean log contrast sensitivity under photopic (top left and top right) and mesopic (bottom left and bottom right) conditions with and without glare were similar in both groups at all spatial frequencies ($P > .05$).

Figure 6 shows the mean photopic and mesopic log contrast sensitivity without and with glare for IC-8 IOL eyes and monofocal eyes in contralateral patients at 12 months. Under photopic conditions (top left and top right), the mean log contrast sensitivity was similar between groups at all spatial frequencies ($P > .05$). Under mesopic conditions (bottom left and bottom right), the mean log contrast sensitivity was on average approximately 0.2 log units lower in the IC-8 IOL eyes



Figures 5. Mean log contrast sensitivity binocular photopic without glare (top left), photopic with glare (top right), mesopic without glare (bottom left), and mesopic with glare (bottom right) for contralateral and bilateral patients at 12 months postoperatively. Error bars represent 95% confidence intervals.

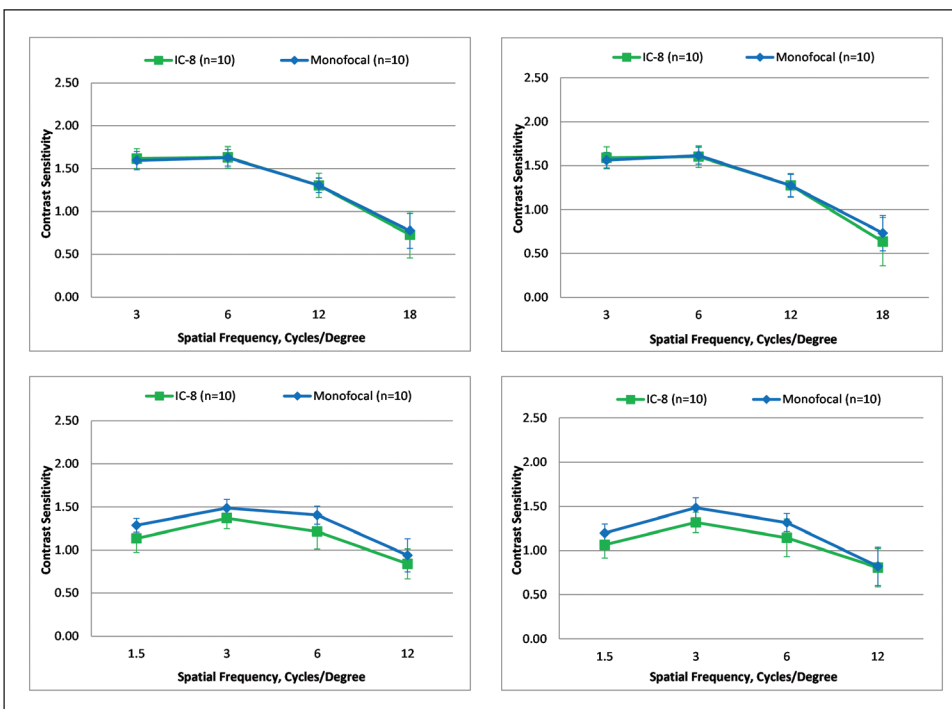


Figure 6. Mean log contrast sensitivity monocular photopic without glare (top left), photopic with glare (top right), mesopic without glare (bottom left), and mesopic with glare (bottom right) for IC-8 IOL (AcuFocus, Irvine, CA) eyes and monofocal eyes in contralateral patients at 12 months postoperatively. Error bars represent 95% confidence intervals. IOL = intraocular lens

compared to monofocal eyes, although none of the differences was statistically significant at any spatial frequency with or without glare conditions ($P > .05$).

PATIENT SATISFACTION, TASK PERFORMANCE, AND VISUAL SYMPTOMS

The mean \pm SD (95% CI) scores for satisfaction and near, intermediate, and distance vision tasks at 12

months are presented in **Table 1** for contralateral and bilateral patients. There were no significant differences in mean satisfaction scores between the postoperative visits in either group ($P > .05$). All contralateral and bilateral patients said they would have the procedure again. The mean scores were slightly better but not statistically significant at the .05 level for bilateral patients on three tasks: reading numbers on a mobile phone (P

TABLE 1
**Scores for Satisfaction and Near, Intermediate, and Distance Vision Tasks
for Contralateral and Bilateral Patients at 12 Months Postoperatively**

Satisfaction and Tasks	Contralateral (n = 10) Mean ± SD (95% CI)	No.	Bilateral (n = 10) Mean ± SD (95% CI)	No.
Satisfaction with overall vision	5.7 ± 0.8 (5.1, 6.3)	10	5.9 ± 1.2 (5.0, 6.8)	6
Satisfaction without reading glasses	5.6 ± 0.8 (5.0, 6.2)	10	6.0 ± 0.9 (5.3, 6.7)	9
How often do you wear reading glasses?	6.1 ± 1.4 (5.1, 7.1)	10	6.9 ± 0.3 (6.7, 7.1)	10
Reading a newspaper or menu	5.7 ± 0.7 (5.2, 6.2)	10	5.7 ± 1.2 (4.9, 6.5)	10
Reading a book	5.6 ± 0.8 (5.0, 6.2)	10	6.0 ± 0.7 (5.5, 6.5)	9
Viewing a computer screen	5.7 ± 0.6 (4.2, 7.1)	3	5.7 ± 0.6 (4.2, 7.1)	3
Numbers on mobile phone	5.4 ± 0.8 (4.8, 6.0)	10	6.1 ± 0.9 (5.5, 6.7)	10
Seeing small print (stock quotes, medicine labels, etc.)	3.9 ± 1.3 (3.0, 4.8)	10	4.3 ± 1.2 (3.5, 5.1)	10
Performing small item tasks such as sewing	4.5 ± 1.2 (3.2, 5.8)	6	4.3 ± 0.8 (3.5, 5.2)	6
Watching a movie	6.0 ± 0.7 (5.5, 6.5)	9	6.2 ± 1.1 (5.4, 7.1)	9
Watching TV	6.1 ± 0.7 (5.6, 6.6)	10	6.2 ± 1.3 (5.3, 7.1)	10
Day driving	5.7 ± 0.6 (4.2, 7.1)	3	6.7 ± 0.6 (5.2, 8.1)	3
Night driving	4.7 ± 0.6 (3.2, 6.1)	3	5.3 ± 0.6 (3.9, 6.8)	3
Sports and other leisure activities	6.1 ± 0.6 (5.6, 6.6)	9	6.7 ± 0.5 (6.3, 7.2)	7
Judging distances	5.8 ± 0.6 (5.3, 6.3)	10	6.0 ± 1.3 (5.0, 7.0)	10

SD = standard deviation; CI = confidence interval

TABLE 2
**Mean ± SD (95% CI) Severity Scores for All Visual Symptoms in
Contralateral and Bilateral Patients at 12 Months Postoperatively^a**

Visual Symptom	Contralateral (n = 10) Average of IC-8 & Monofocal IOL Eyes (No. of Eyes = 20)	Bilateral (n = 10) Average of 2 IC-8 IOL Eyes (No. of Eyes = 20)
Blurry/fluctuating vision	1.3 ± 1.1 (0.5, 2.1)	0.7 ± 0.9 (0.1, 1.3)
Color disturbances	0.0 ± 0.0 (0.0, 0.0)	0.0 ± 0.0 (0.0, 0.0)
Distortion	0.1 ± 0.3 (-0.1, 0.3)	0.1 ± 0.2 (-0.1, 0.2)
Dryness	1.4 ± 0.7 (0.9, 1.9)	1.7 ± 1.3 (0.7, 2.6)
Glare	0.6 ± 1.0 (-0.1, 1.2)	1.0 ± 0.8 (0.4, 1.5)
Halos	0.6 ± 1.0 (-0.2, 1.4)	1.2 ± 1.3 (0.3, 2.1)
Night vision problems	0.3 ± 0.9 (-0.4, 1.0)	0.9 ± 1.1 (0.0, 1.7)
Pain/burning	0.0 ± 0.0 (0.0, 0.0)	0.3 ± 0.8 (-0.3, 0.9)
Double vision	0.5 ± 1.0 (-0.3, 1.2)	0.4 ± 0.7 (-0.1, 0.8)
Ghost/overlapping images	0.3 ± 0.5 (-0.1, 0.6)	0.4 ± 0.7 (-0.1, 0.8)

SD = standard deviation; CI = confidence interval; IOL = intraocular lens

^aThe symptoms were reported for each eye, and the average of the reported scores from both eyes was used for each patient.
The IC-8 IOL is manufactured by Acufocus, Irvine, CA.

= .054), driving during the day ($P = .099$), and playing sports ($P = .050$). Contralateral patients reported slightly higher scores on performing small item tasks such as sewing, whereas bilateral patients rated slightly higher scores on other near and distance tasks, although these differences were not statistically significant ($P > .10$). There were no significant differences on the mean

scores between all postoperative visits in both contralateral and bilateral patients ($P > .05$).

Table 2 presents the mean (95% CI) severity scores for all visual symptoms in contralateral and bilateral patients at 12 months. The mean severity score for blurry/fluctuating vision was slightly worse for contralateral patients than for bilateral patients, whereas

the mean scores for dryness, glare, halos, night vision problems, and pain/burning were slightly worse for bilateral patients than for contralateral patients. None of these differences were statistically significant ($P > .05$). In addition, no correlations were found between pupil size, patient satisfaction, and visual symptoms.

ADVERSE EVENTS

During the follow-up period, no serious adverse events occurred. Two IC-8 IOL eyes (6.7% of IC-8 IOL eyes) developed clinically significant posterior capsular opacification. One eye was treated with YAG capsulotomy during the 12-month follow-up. UDVA and CDVA at all distances (far, intermediate, and near) improved after YAG laser treatment. At the 12-month follow-up examination, UDVA was 0.1 logMAR for far, -0.02 logMAR for intermediate, and 0.0 logMAR for near. To perform a YAG capsulotomy in an IC-8 IOL eye, an omega pattern technique was used. In this technique, laser spots are fired around the periphery of the IOL mask, leaving a portion of the posterior capsulotomy connected to the capsule at the bottom. The capsulotomy flap then floats down out of view.

DISCUSSION

In the current study, the visual effects of bilateral implantation of the IC-8 IOL in comparison to contralateral implantation were evaluated. It could be shown that the combination of a small-aperture IOL and micromonovision allows an improvement of visual performance, especially in the intermediate and near range. The improvement in binocular UIVA and UNVA was 0.5 to 1 line greater in bilateral patients. Bilateral patients had better overall satisfaction, satisfaction with near tasks, and spectacle independence and they rated many near tasks to be easier to perform. Bilateral patients rated ease of driving slightly better than contralateral patients. They also reported experiencing slightly more glare and halos, whereas contralateral patients experienced slightly more blurry/fluctuating vision and double vision, with none reaching statistical significance. The higher-level satisfaction expressed by patients with bilateral IC-8 IOLs versus contralateral implantation is likely due to the patient selection process. Patients self-selected bilateral implantation after having a positive response to the result achieved in their first eye treated with the IC-8 IOL. Binocularity also delivered increased range of vision at intermediate and near for these patients, which may also have contributed to the higher satisfaction scores. Dick et al.⁶ compared 11 contralateral to 6 bilateral patients. Visual acuity comparisons between the two groups were similar

to the results from our study, with bilateral patients showing significantly better binocular UIVA, UNVA, DCIVA, and DCNVA. However, in contrast to our study, they reported lower patient satisfaction scores by bilateral patients. This difference may be attributed to a difference in enrollment criteria. In our study, only patients who voluntarily expressed their desire to have the IC-8 IOL in their second eye after their first eye was treated were enrolled into the study. Additionally, if the patient reported dissatisfaction with the range of vision in the first treated eye, the target refraction could be adjusted for the second eye to compensate for that dissatisfaction. In the study conducted by Dick et al., both eyes were treated regardless of the patient response to the first treated eye.

Visual outcomes with both contralateral and bilateral implantation can be optimized by improving the range of clear vision by aiming for a postoperative myopic MRSE in the IC-8 IOL eye. The small magnitude of myopia in the IC-8 IOL eye extends the near vision range by almost 1.00 D.^{2,6,7} In this study, if the first eye had achieved the targeted myopia and the patient was not satisfied with far vision, then the second eye was targeted for emmetropia. However, if the patient was not satisfied with near vision, a slightly more myopic outcome was targeted in the second eye.

The IC-8 IOL has been recommended for implantation in the non-dominant eye for contralateral implantation.² The concept of the usefulness of eye dominance is debatable, and dominance determination may be unreliable in the presence of a cataract.⁸ For pseudophakic monovision, either eye implanted for near or far appears to work equally well in terms of patient satisfaction, visual function, and spectacle independence.⁹ Additionally, ocular dominance has been shown to change following cataract surgeries.¹⁰ Implantation of the IC-8 IOL was not based on eye dominance in this study and, irrespective of the eye dominance, all patients in this study achieved good visual acuity, patient satisfaction, and low visual symptoms scores.

Due to its optical design, the small-aperture IOL is able to tolerate a wide range of spherical and cylindrical refractive errors.^{2,11} Therefore, the IC-8 IOL may be an excellent option for patients with corneal astigmatism up to -1.50 D or for patients in whom the risk of a postoperative refractive surprise is anticipated, such as after keratorefractive surgery. IC-8 IOL implantation in patients with iridocorneal irregularities has been shown to decrease dyphotopsia and improve visual outcomes.¹²⁻¹⁴ Similar to the IC-8 IOL, the pinhole iris-fixated diaphragm IOL when implanted in patients with severe dysphotopsia as a result of keratoconus has been shown to sig-

nificantly decrease dysphotopsia.¹⁵ Increases in the magnitude of dysphotopsia following refractive surgeries is related to induction of higher order aberrations, which are known to decrease with reduction in pupil size.¹⁶⁻¹⁹ Therefore, bilateral implantation of the IC-8 IOL may be a viable option for patients with iridocorneal irregularities, keratoconus, and prior refractive surgeries.

In this study, no systematic correlations were found between pupil size, patient satisfaction, and visual symptoms. This is likely due to the small sample size and the variability in the pupil size measurement, the overall low ratings of symptom scores if any were reported, and overall high satisfaction scores. The strengths of the study are a single surgeon with a single surgical technique and consistent IOL power selection. However, this study also had its limitations: the patients were not randomized in terms of who would be receiving contralateral versus bilateral IC-8 IOL implantation and the small sample size in both groups because this was a pilot study of bilateral implantation of the IC-8 IOL. Our study results only refer to patients with low preoperative corneal astigmatism (< 1.75 D). IC-8 IOL implantation in patients with higher astigmatism and/or irregular astigmatism should be further investigated to demonstrate the potential superiority of IC-8 IOL implantation both contralateral and bilateral versus other IOLs.

Implantation of the IC-8 IOL in patients with or without a monofocal IOL in the fellow eye is an excellent option for correcting presbyopia following cataract removal. Likewise, bilateral implantation of the IC-8 IOL can be successful based on careful patient selection.

AUTHOR CONTRIBUTIONS

Study concept and design (REA); data collection (REA); analysis and interpretation of data (REA); writing the manuscript (REA); critical revision of the manuscript (REA); statistical expertise (REA); administrative, technical, or material support (REA); supervision (REA)

REFERENCES

1. Grabner G, Ang RE, Vilupuru S. The small-aperture IC-8 intraocular lens: a new concept for added depth of focus in cataract patients. *Am J Ophthalmol*. 2015;160(6):1176-1184. doi:10.1016/j.ajo.2015.08.017
2. Dick HB, Piovella M, Vukich J, et al. Prospective multicenter trial of a small-aperture intraocular lens in cataract surgery. *J Cataract Refract Surg*. 2017;43(7):956-968. doi:10.1016/j.jcrs.2017.04.038
3. Tucker J, Charman WN. The depth-of-focus of the human eye

- for Snellen letters. *Am J Optom Physiol Opt*. 1975;52(1):3-21. doi:10.1097/00006324-197501000-00002
4. Vilupuru S, Lin L, Pepose JS. Comparison of contrast sensitivity and through focus in small-aperture inlay, accommodating intraocular lens, or multifocal intraocular lens subjects. *Am J Ophthalmol*. 2015;160(1):150-162. doi:10.1016/j.ajo.2015.04.023
5. Lin L, van de Pol C, Vilupuru S, Pepose JS. Contrast sensitivity in patients with emmetropic presbyopia before and after small-aperture inlay implantation. *J Refract Surg*. 2016;32(6):386-393. doi:10.3928/1081597X-20160217-04
6. Dick HB, Elling M, Schultz T. Binocular and monocular implantation of small-aperture intraocular lenses in cataract surgery. *J Refract Surg*. 2018;34(9):629-631. doi:10.3928/1081597X-20180716-02
7. Eppig T, Spira C, Seitz B, Szentmáry N, Langenbucher A. A comparison of small aperture implants providing increased depth of focus in pseudophakic eyes. *Z Med Phys*. 2016;26(2):159-167. doi:10.1016/j.zemedi.2016.03.003
8. Mapp AP, Ono H, Barbeito R. What does the dominant eye dominate? A brief and somewhat contentious review. *Percept Psychophys*. 2003;65(2):310-317. doi:10.3758/BF03194802
9. Zhang F, Sugar A, Arbisser L, Jacobsen G, Artico J. Crossed versus conventional pseudophakic monovision: patient satisfaction, visual function, and spectacle independence. *J Cataract Refract Surg*. 2015;41(9):1845-5. doi:10.1016/j.jcrs.2015.10.013
10. Schwartz R, Yatziv Y. The effect of cataract surgery on ocular dominance. *Clin Ophthalmol*. 2015;9:2329. doi:10.2147/OPTH.S93142
11. Ang RE. Small-aperture intraocular lens tolerance to induced astigmatism. *Clin Ophthalmol*. 2018;12:1659-1664. doi:10.2147/OPTH.S172557
12. Shajari M, Mackert MJ, Langer J, et al. Safety and efficacy of a small aperture capsular bag fixated intraocular lens in eyes with severe corneal irregularities [published online head of print August 16, 2019]. *J Cataract Refract Surg*. doi:10.1016/j.jcrs.2019.09.002
13. Schultz T, Dick HB. Small-aperture intraocular lens implantation in a patient with an irregular cornea. *J Refract Surg*. 2016;32(10):706-708. doi:10.3928/1081597X-20160721-01
14. Ziaei M, Mearza AA. Corneal inlay implantation in a young pseudophakic patient. *J Cataract Refract Surg*. 2013;39(7):1116-1117. doi:10.1016/j.jcrs.2013.04.025
15. Muñoz G, Rohrweck S, Sakla HF, Altroudi W. Pinhole iris-fixated intraocular lens for dysphotopsia and photophobia. *J Cataract Refract Surg*. 2015;41(3):487-491. doi:10.1016/j.jcrs.2015.02.001
16. Cerviño A, Villa-Collar C, Gonzalez-Mejome JM, Ferrer-Blasco T, García-Lázaro S. Retinal straylight and light distortion phenomena in normal and post-LASIK eyes. *Graefes Arch Clin Exp Ophthalmol*. 2011;249(10):1561-1566. doi:10.1007/s00417-010-1583-7
17. McCormick GJ, Porter J, Cox I, MacRae S. Higher order aberrations in eyes with irregular corneas after laser refractive surgery. *Invest Ophthalmol Vis Sci*. 2004;45(13):218.
18. Martínez CE, Applegate RA, Klyce SD, McDonald MB, Medina JP, Howland HC. Effect of pupillary dilation on corneal optical aberrations after photorefractive keratectomy. *Arch Ophthalmol*. 1998;116(8):1053-1062. doi:10.1001/archophth.116.8.1053
19. Ghaith AA, Daniel J, Stulting RD, Thompson KP, Lynn M. Contrast sensitivity and glare disability after radial keratotomy and photorefractive keratectomy. *Arch Ophthalmol*. 1998;116(1):12-18. doi:10.1001/archophth.116.1.12

TABLE A
MRSE at Preoperative and Postoperative Visits and Preoperative Topographical Corneal Astigmatism for the IC-8 IOL Eyes in Bilateral and Contralateral Patients

Visit	Contralateral (IC-8 IOL Eye Only)			Bilateral (1st IC-8 IOL Eye)			Bilateral (2nd IC-8 IOL Eye)		
	No.	Mean \pm SD (95% CI)	Min, Max	No.	Mean \pm SD (95% CI)	Min, Max	No.	Mean \pm SD (95% CI)	Min, Max
MRSE (D)									
Preoperative	10	0.55 \pm 1.36 (-0.42, 1.52)	-1.75, 2.50	10	1.18 \pm 0.82 (0.59, 1.77)	-0.88, 2.00	9	0.90 \pm 0.57 (0.46, 1.34)	0.25, 1.75
1 month postoperative	10	-0.56 \pm 0.39 (-0.84, -0.28)	-1.25, 0.13	10	-0.44 \pm 0.35 (-0.69, -0.19)	-1.00, 0.00	10	-0.38 \pm 0.28 (-0.58, -0.18)	-0.75, 0.00
3 months postoperative	10	-0.53 \pm 0.55 (-0.92, -0.14)	-1.25, 0.00	10	-0.51 \pm 0.38 (-0.78, -0.24)	-1.25, 0.00	10	-0.41 \pm 0.37 (-0.67, -0.15)	-1.13, 0.00
6 months postoperative	10	-0.73 \pm 0.92 (-1.39, -0.07)	-2.25, 0.50	10	-0.36 \pm 0.31 (-0.58, -0.14)	-0.75, 0.00	10	-0.58 \pm 0.45 (-0.90, -0.26)	-1.50, 0.00
9 months postoperative	9	-0.50 \pm 0.38 (-0.79, -0.21)	-1.25, -0.13	10	-0.56 \pm 0.51 (-0.92, -0.20)	-1.38, 0.00	9	-0.50 \pm 0.43 (-0.83, -0.17)	-1.13, 0.00
12 months postoperative	10	-0.58 \pm 0.80 (-1.15, -0.01)	-2.38, 0.00	10	-0.33 \pm 0.44 (-0.64, -0.02)	-1.25, 0.13	10	-0.60 \pm 0.46 (-0.93, -0.27)	-1.38, 0.00
Corneal astigmatism (D)									
Preoperative	10	0.67 \pm 0.32 (0.44, 0.89)	0.31, 1.26	10	0.48 \pm 0.23 (0.31, 0.64)	0.12, 0.81	10	0.57 \pm 0.27 (0.37, 0.76)	0.23, 0.98

MRSE = mean manifest spherical equivalent; IOL = intraocular lens; SD = standard deviation; CI = confidence interval; min = minimum; max = maximum; D = diopters
The IC-8 IOL is manufactured by Acufocus, Irvine, CA.